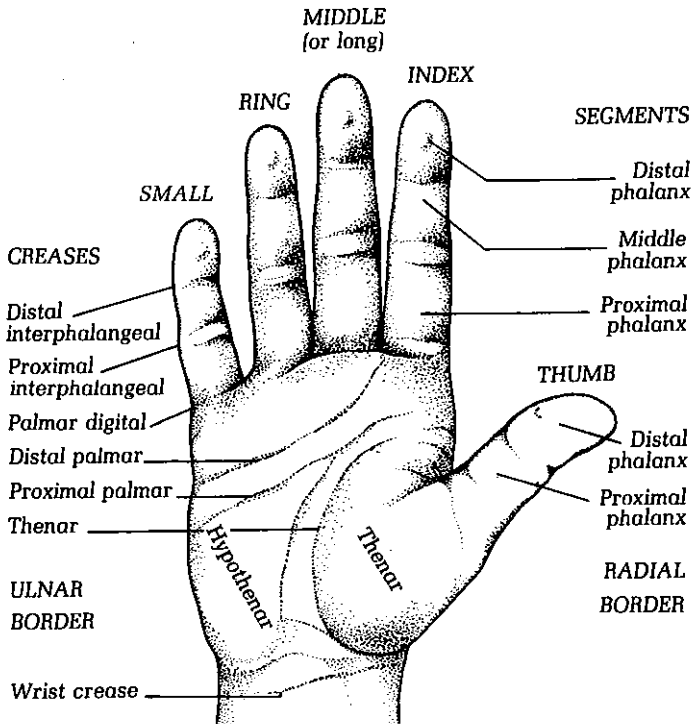




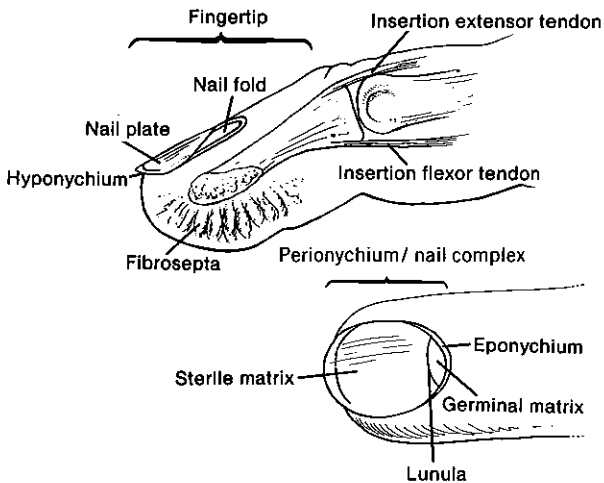
Hand Anatomy

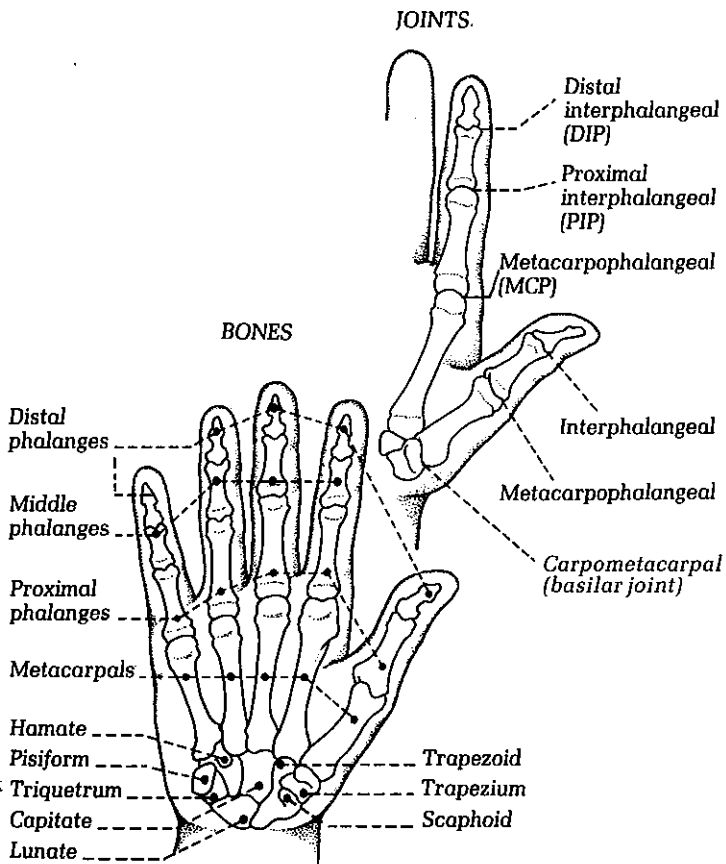
Use the following diagrams to better understand your diagnosis, or to help describe your condition to your health care professional.

SURFACE ANATOMY
(Palmar surface)

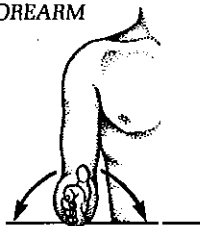


FINGERTIP AND NAIL COMPLEX





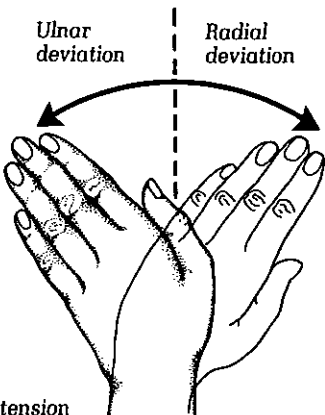
FOREARM



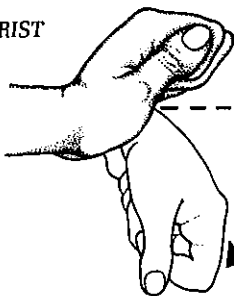
Supination Pronation

Ulnar
deviation

Radial
deviation



WRIST

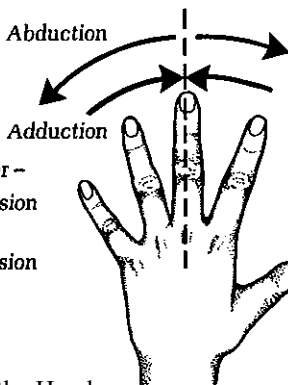


Extension

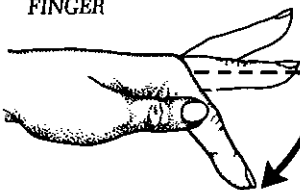
Flexion

Abduction

Adduction



FINGER



Hyper-
extension

Extension

Flexion

